
Purina® PRO PLAN® Symposium 2026
Navigating Microbiota Dynamics
Applicable to Pet Nutrition



**Chronic Enteropathy II: Fecal Microbiota
Transplantation in Dogs with Chronic
Enteropathy**



**Linda Toresson, DVM, Swedish Specialist in
Small Animal Internal Medicine , PhD**



"Jazz", Border collie, intact female, 6 months of age

Medical history:

Watery diarrhea, intermittent melena, poor BCS and hyporexia since 8 w of age, intermittent profound vomiting

Hospitalized 3 times (dehydration + vomiting)

Dietary trials: Highly digestible GI diets x2, Low calory GI diet x 1, Hydrolyzed protein diet x2

Medical txs:

- Fenbendazole 50 mg/kg q24h x 5d. – even worse
- Metronidazole (9 + 7 d.) 2 courses: melena stopped, improved appetite, still diarrhea
- Prednisolone 1 mg/kg q24h x 7 d - 1 mg/kg q48h - partial response, melena stopped, improved appetite - transient
- Amoxicillin added after last hospitalization



"Jazz", Border collie, intact female, 6 months of age – select previous diagnostics

Repeated fecal parasite testing: negative


CBC + serum biochemistry:

CRP (mg/L)	94	(0 – 10)
Monocytes	2,00	x10 ⁹ /L (0,16 - 1,12)

GI panel:

Cobalamin (pmol/l)	214	(163-733)
Folate (nmol/l)	11	(9-50)
TLI	34	(5.2-35.0)
Basal cortisol*	<10	(0-160) *on corticosteroid tx

Abdominal ultrasound scan: mildly increased SI wall thickness, mild fluid accumulation btw. intestinal loops, enlarged jejunal lymph nodes, (3.8 x 2.8 cm)



"Jazz", Border collie, intact female, 6 months of age – 1st referral consultation

Severe hyporexia - refuses to take any kibble diet - dog owner started feeding a home-cooked diet: chicken gizzard, minced beef and brown rice

Normal appetite on home-cooked diet, slightly improved fecal scores
- 6/7 to 5/7

Clinical examination:

BAR

BCS **2/9**


Poor coat quality

Mucus membranes slightly pale

No abdominal pain or abnormalities

Hematocrit **31%**, albumin and cholesterol within RI

Dysbiosis index **3.3**



"Jazz", Border collie, intact female, 6 months of age – treatment

3 FMT's as rectal enema with 14 days interval

After FMT 1 – intermittent normal feces mixed with diarrhea, more alert, improved coat quality

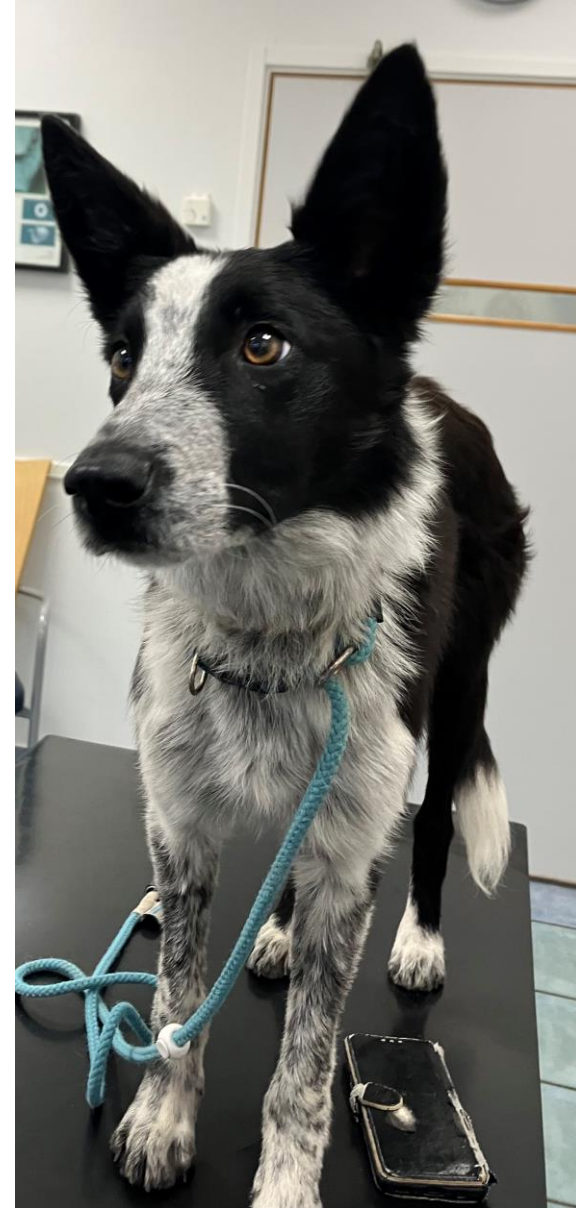Relapsed with diarrhea and hyporexia 3 days before FMT 2

At FMT 2: Dysbiosis index **2.0**

After FMT 2 –appetite ↑ ↑, fecal scores 4-5/7

Started psyllium powder, 10 ml q 24 hrs

At FMT 3 – DI – 2.0, much more active/playful, fecal score 2/7 x 2-3



Additional treatment:

- Cobalamin
- Nutritional consultation – balanced home-cooked diet

After FMT 3:

Started tapering corticosteroids

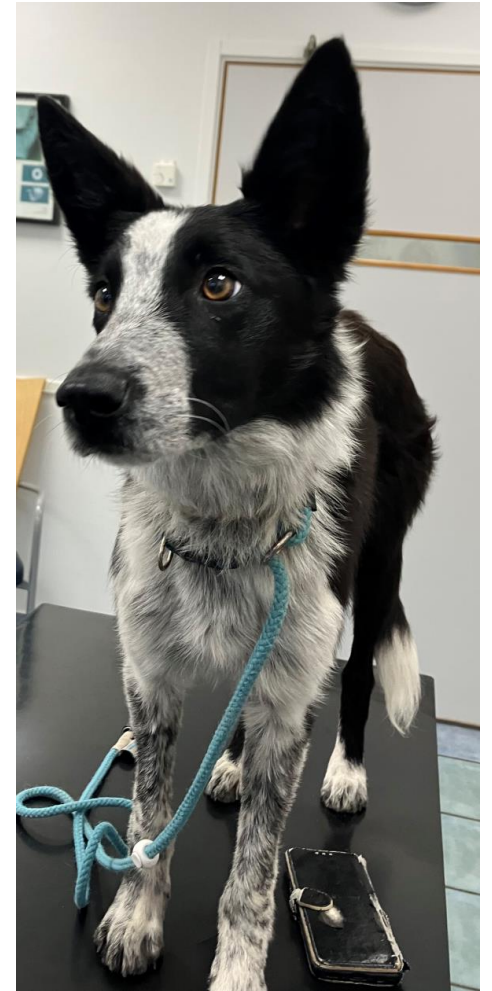Relapse after running away and feasting on a dead rabbit

JAVMA

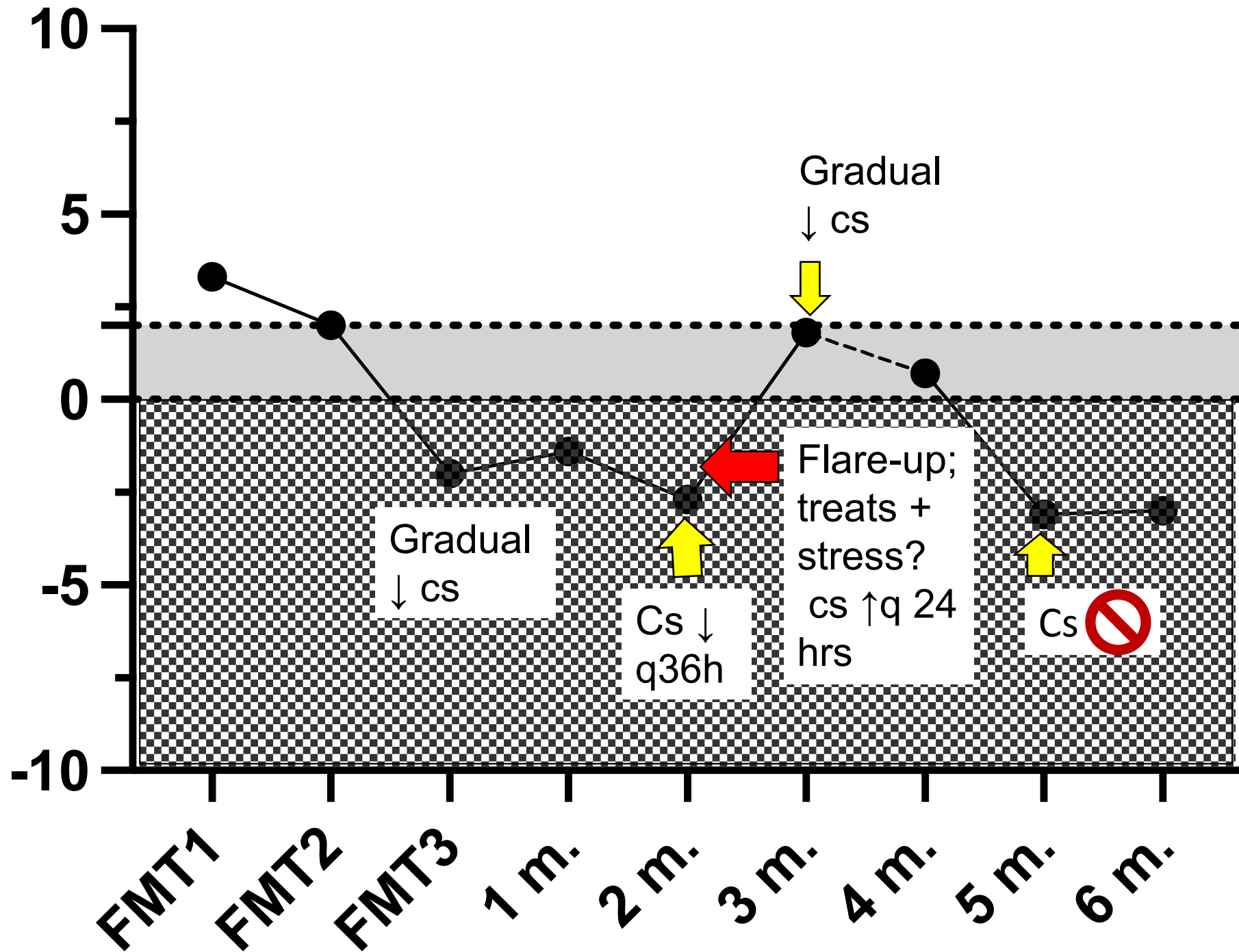


Repeated fecal microbiota transplantation in dogs with chronic enteropathy can decrease disease activity and corticosteroid usage

Linda Toresson, DVM, PhD^{1,2*} ; Ulrika Ludvigsson, DVM² ; Gunilla Olmedal, DVM²; Josefin Hellgren, DVM²; Michaela Toni, DVM²; Paula R. Giaretta, MedVet, DACVP, PhD¹ ; Jan S. Suchodolski, Dr med vet, PhD, DACVM¹ 



Dysbiosis index



"Jazz", Border collie, intact female, 1 year of age

- Active working Border collie, normal BCS
- Cobalamin supplementation q48h, no other meds
- Home-cooked diet, sensitive to treats etc
- Dysbiosis index – 0.8

6 months later:

- Stopped cobalamin supplementation, normal serum concentrations 1 month later



Jazz, 1.5 year of age

Fecal microbial transplantation (FMT)

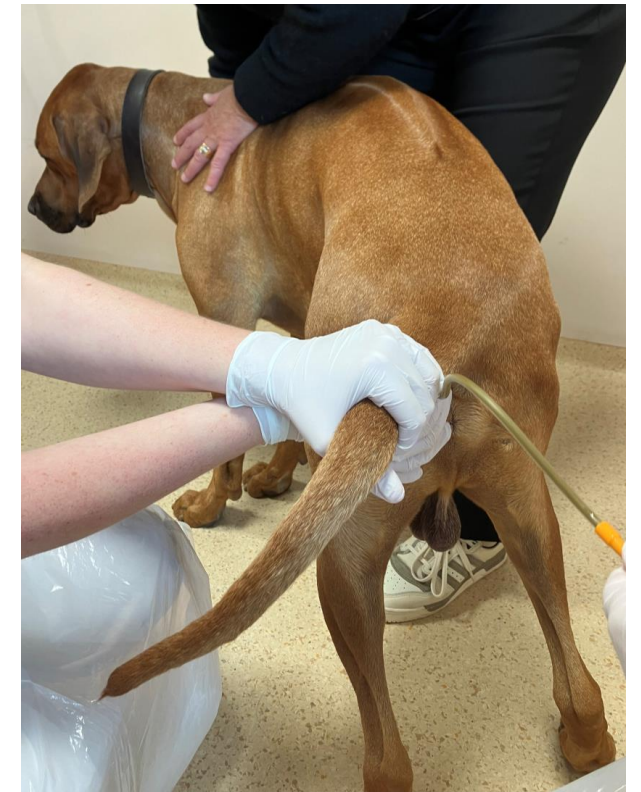FMT → transfer microbiota from healthy donor to a recipient with a disease → improve the microbiome/decrease disease activity



+



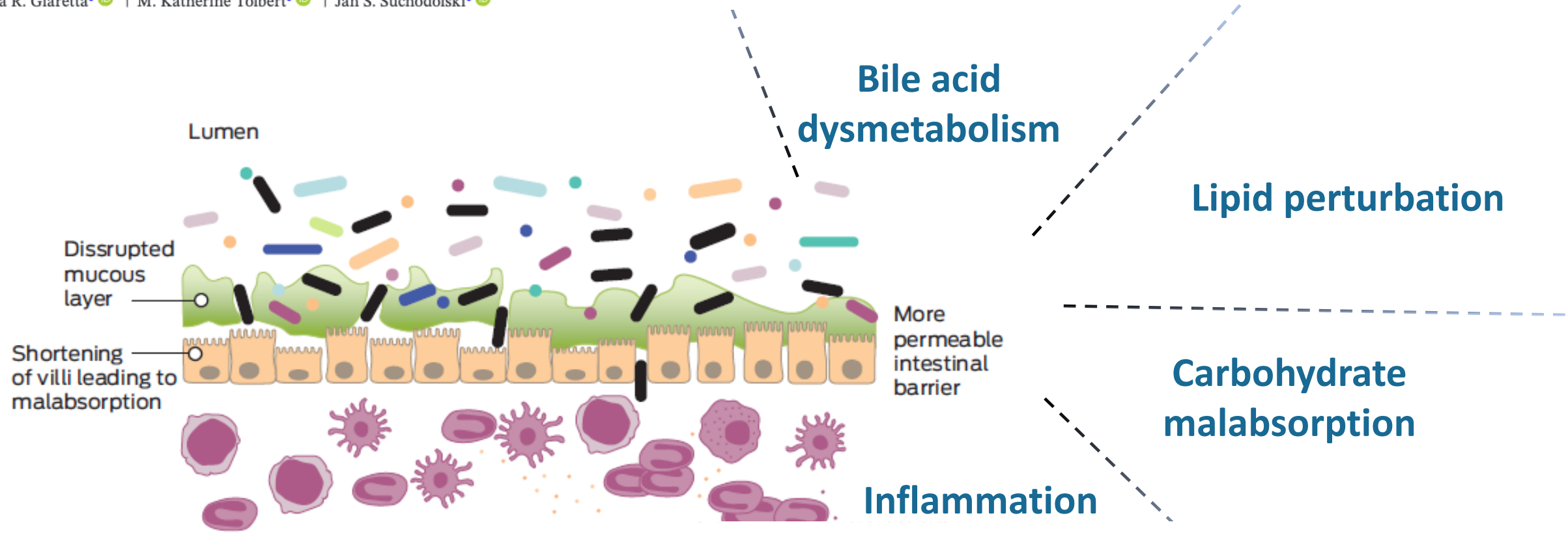
+




Fecal and Clinical Profiles of Dogs With Chronic Enteropathies Treated With Bile Acid Sequestrants for 5–47 Months: A Retrospective Case Series

altered GI functionality

Linda Toresson^{1,2} | Amanda B. Blake¹ | Chi-Hsuan Sung¹ | Gunilla Olmedal² | Ulrika Ludvigsson² | Paula R. Giaretta¹ | M. Katherine Tolbert¹ | Jan S. Suchodolski¹




 Dysbiotic and reduced bacterial diversity

Microbial Gene Profiling and Targeted Metabolomics in Fecal Samples of Dogs With Chronic Enteropathy With or Without Increased Dysbiosis Index

Chih-Chun Chen¹ | Rachel Pilla¹ | Linda Toresson^{1,2} | Chi-Hsuan Sung¹ | Amanda B. Blake¹ | Bruna Correa Lopes¹ | Jonathan Turck¹ | Albert E. Jergens³ | Stacie C. Summers⁴ | Stefan Unterer⁵ | Patricia Eri Ishii^{1,6} | Paula R. Giaretta¹ | M. Katherine Tolbert¹ | Jan S. Suchodolski¹

FMT in people:



Mentioned in a Chinese textbook of emergency medicine in 320 A.D (Hong Ge)

Excellent effect in chronic recurrent *Clostridioides difficile* inf. – better than antibiotics (Chapman et al 2016)

Grade 1 evidence in treating ulcerative colitis and Crohn's disease (Paramsothy et al 2017; Cheng et al 2021)

Fresh or frozen feces from healthy donors **equally effective**


Can be deposited in the colon, duodenum or orally - **equally effective**



=fertilizer




=new grass seeds



=new eco system

FMT response and dysbiosis



FMT-responders with ulcerative colitis had less marked dysbiosis vs non-responders at inclusion (Paramsothy et al., 2019, Kang et al 2022)


Responder had a higher % of fecal secondary BAs at baseline and post FMT

Specific Bacteria and Metabolites Associated With Response to Fecal Microbiota Transplantation in Patients With Ulcerative Colitis



Gastroenterology 2019;156:1440–1454

Sudarshan Paramsothy,^{1,2,3,5,6} Shaun Nielsen,¹ Michael A. Kamm,⁴ Nandan P. Deshpande,¹ Jeremiah J. Faith,² Jess C. Clements,² Ramesh Paramsothy,⁷ Alison J. Walsh³



Gut and Liver

<https://doi.org/10.5009/gnl210369>
pISSN 1976-2283 eISSN 2005-1212

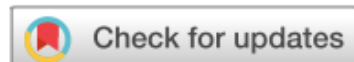

Original Article

Exploration of Potential Gut Microbiota-Derived Biomarkers to Predict the Success of Fecal Microbiota Transplantation in Ulcerative Colitis: A Prospective Cohort in Korea

Gi-Ung Kang¹, Sowon Park², Yeongyun Jung¹, Jai J. Jee², Min-Sueng Kim¹, Seungjun Lee³, Dong-Woo Lee⁴, Jae-Ho Shin¹, and Hong Koh²

**”Microbiota-based model was much better at predicting outcomes than the clinical features mode”
(Kang et al)**




JAVMA

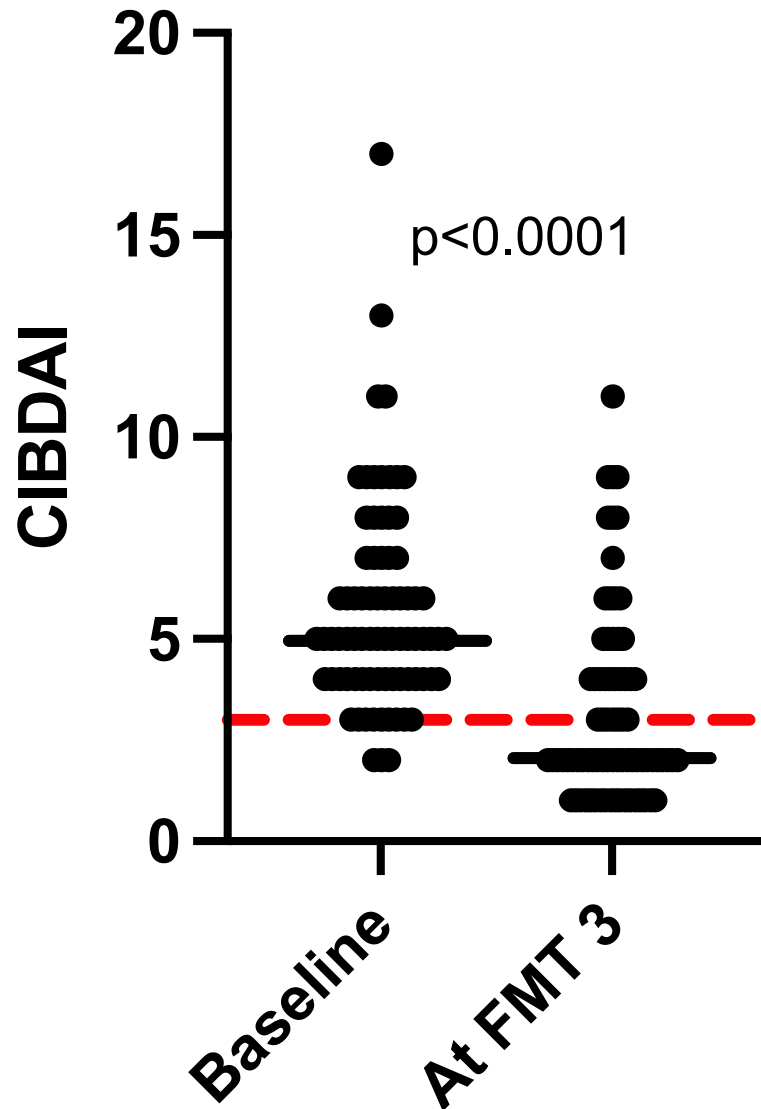


Repeated fecal microbiota transplantation in dogs with chronic enteropathy can decrease disease activity and corticosteroid usage

Linda Toresson, DVM, PhD^{1,2*} ; Ulrika Ludvigsson, DVM² ; Gunilla Olmedal, DVM²; Josefin Hellgren, DVM²; Michaela Toni, DVM²; Paula R. Giaretta, MedVet, DACVP, PhD¹ ; Jan S. Suchodolski, Dr med vet, PhD, DACVM¹ 

C. G. Vecchiato¹ , M. C. Sabetti², C. H. Sung³, F. Sportelli¹, C. Delsante¹, C. Pinna¹, M. Alonzo⁴, D. Erba⁴, J. S. Suchodolski³, R. Pilla³, M. Pietra¹, G. Biagi¹ & F. Procoli⁴

Clinical effects of FMT in dogs with NRE or partial immunomodulatory-responsive enteropathy (P-IRE)



- n=80, same repeated rectal FMT protocol
- 74% responded to FMT
 - 78% of responders – long-lasting response (minimum 3 m.)
 - 22% short-lasting response (relapse within 8 w.)

FMT was effective in the majority of dogs with NRE or P-IRE



Article

Clinical Effects of Faecal Microbiota Transplantation as Adjunctive Therapy in Dogs with Chronic Enteropathies—A Retrospective Case Series of 41 Dogs

Linda Toresson 1,2,*^{ORCID}; Thomas Seilmann 1^{ORCID}; Rachel Pilla 3^{ORCID}; Ulrika Ludvigsson 2, Josefin Hellgren 2,

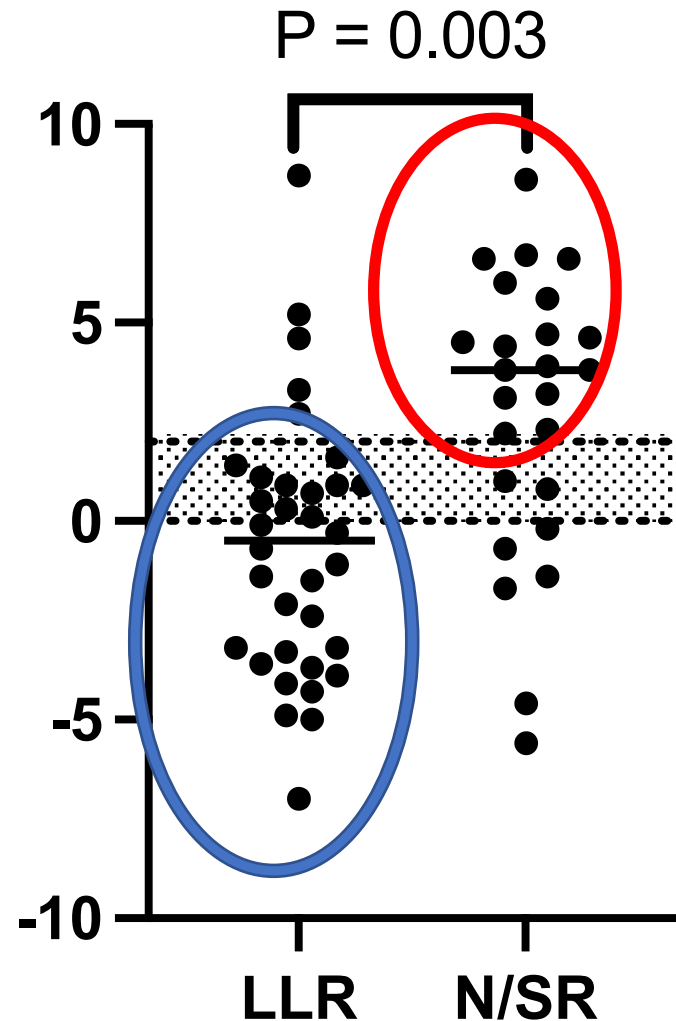
JAVMA



Repeated fecal microbiota transplantation in dogs with chronic enteropathy can decrease disease activity and corticosteroid usage

Linda Toresson, DVM, PhD^{1,2*} ^{ORCID}; Ulrika Ludvigsson, DVM² ^{ORCID}; Gunilla Olmedal, DVM²; Josefin Hellgren, DVM²; Michaela Toni, DVM²; Paula R. Giaretta, MedVet, DACVP, PhD¹ ^{ORCID}; Jan S. Suchodolski, Dr med vet, PhD, DACVM¹ ^{ORCID}

No/mild dysbiosis at baseline – more likely respond to FMT?




Combined data from 3 studies, same FMT protocol, n=59 (Toresson et al 2023, Vecchiato et al 2025, Toresson et al 2025)

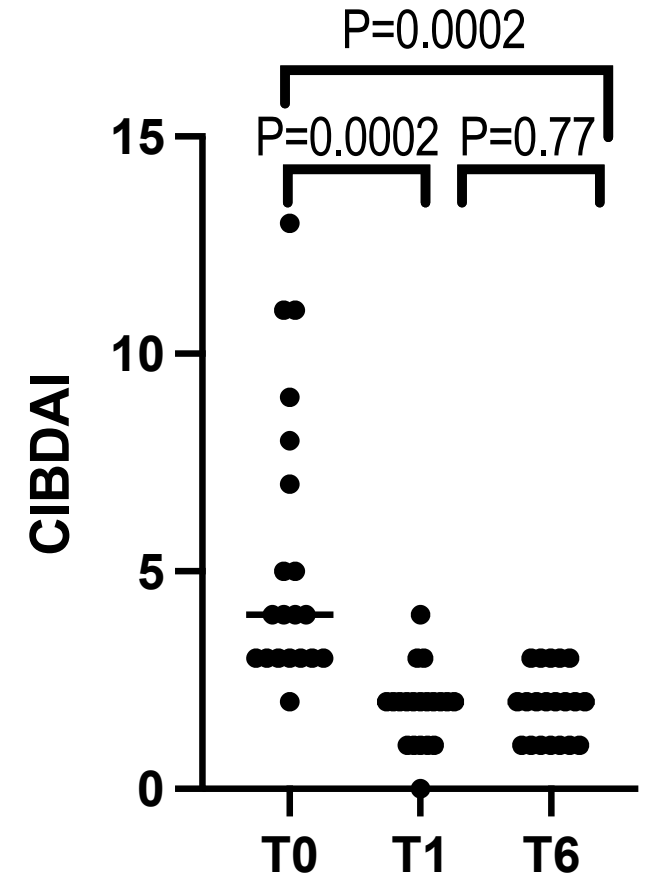
Dogs tx w. antibiotics within 8 w. excluded

No or mild dysbiosis (85 % of LLR) – more likely LLR

Severe dysbiosis (68% of N/SR) – more likely N/SR to FMT

How do most CE dogs respond to FMT?

- Improved fecal quality + increased activity level  most common clinical improvement 42/59 (71%) of responders (combined data; Toresson et al 2023 + Toresson et al 2025)
- Several of these dogs not reported as lethargic before
- Expressed as:
 - Taking more initiatives to play/interact w. owner and/or other dogs
 - More active during walks, longer walks, walking in front of the dog owner instead of behind, more social/inquisitive
- Placebo?
 - Often mentioned by unrelated people (doggy day care, distant friends/relatives)



LLR, Toresson et al 2025

REVIEW

Research Article

Fecal M

Self-assessed quality of life ↑ ↑ for 3-6 months post FMT

Fatigue ↓ ↓ up to 6 months post FMT



lity of

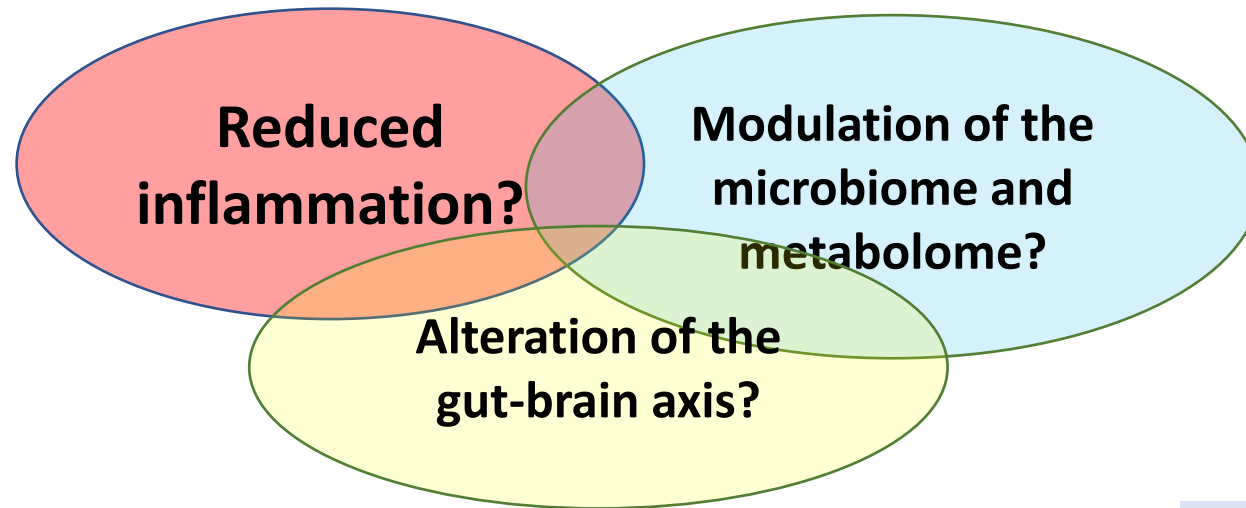


Research paper

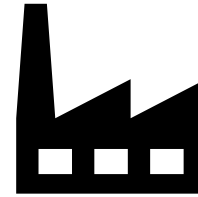

The effect of fecal microbiota transplantation on IBS related quality of life and fatigue in moderate to severe non-constipated irritable bowel: Secondary endpoints of a double blind, randomized, placebo-controlled trial



Peter Holger Johnsen^{a,e,*}, Frank Hilpüsch^{b,d}, Per Christian Valle^a, Rasmus Goll^{c,e}



SCFA



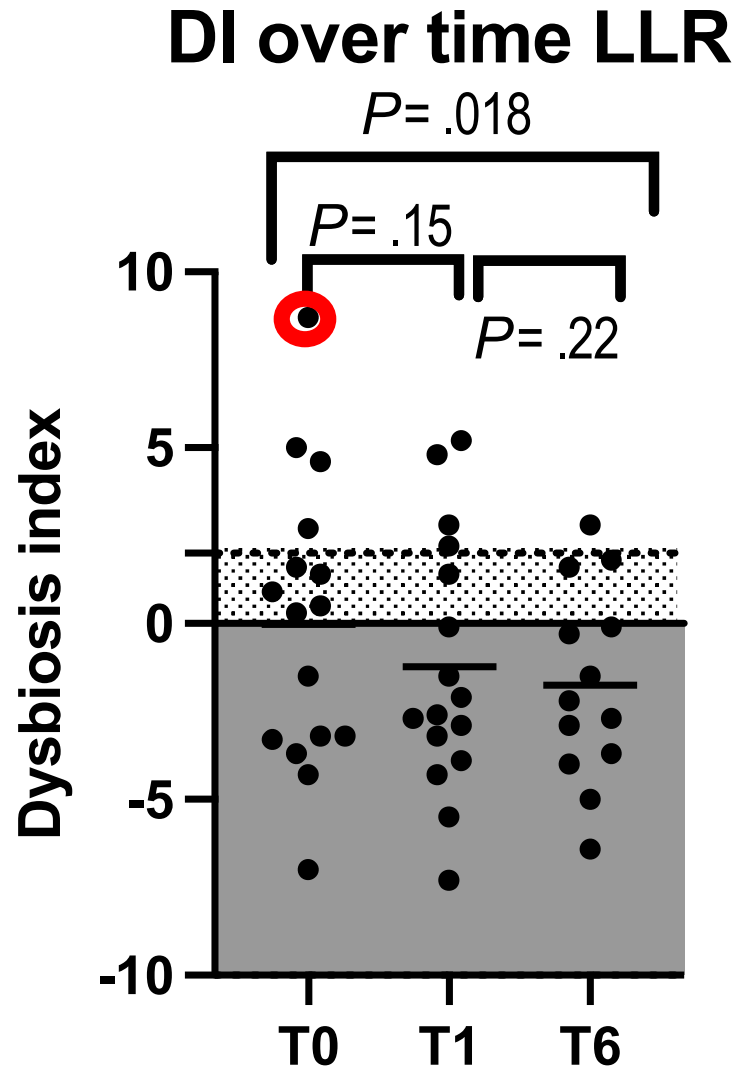
- γ -amino butyric acid (GABA)
- glutamate
- noradrenaline
- dopamine

Gao et al

Advances in Nutrition

Volume 11, Issue 3, May 2020, Pages 709-723

Dysbiosis index over time post FMT



"Kajsa"


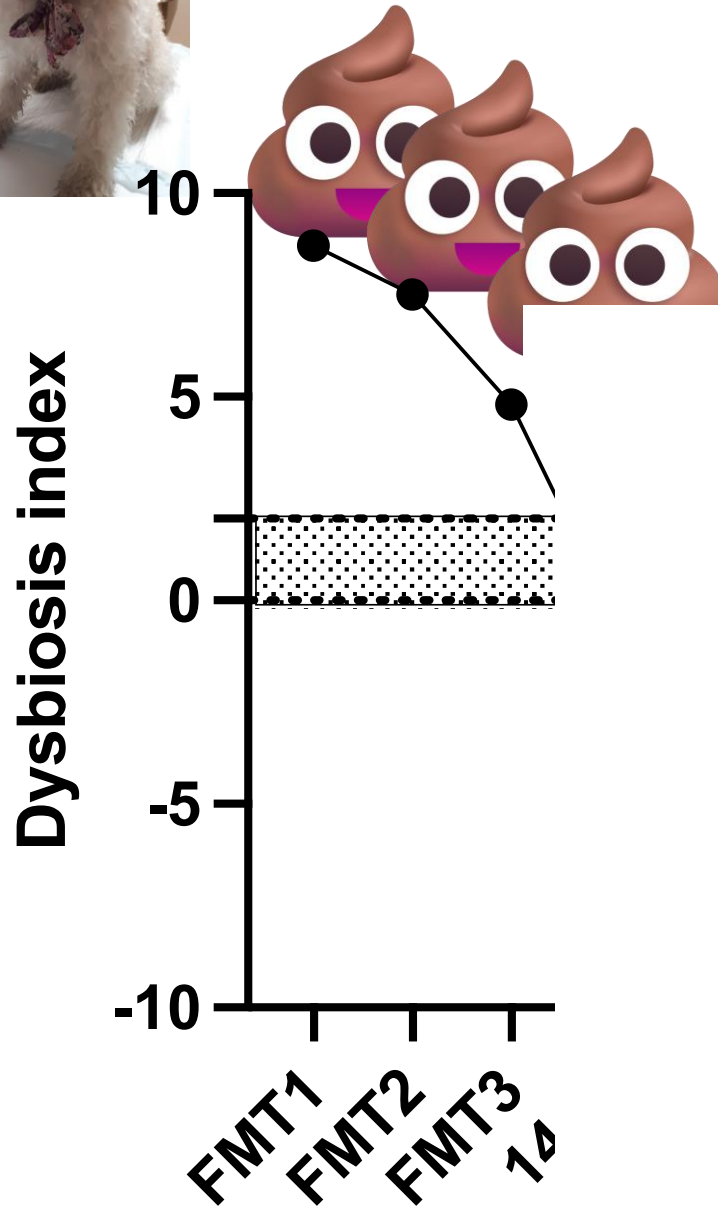

11.3 year old FI medium sized poodle

Tx for CE for 4 years w:

- hydrolyzed diet
- Pred q 48 hrs
- Olsalazine (5-ASA) q 48 hrs

- Diarrhea for 2 months, not responding to diet change.

- Partial response to ↑ Pred





“Alma”, spayed female Golden R., 5 Y/A, P-IRE

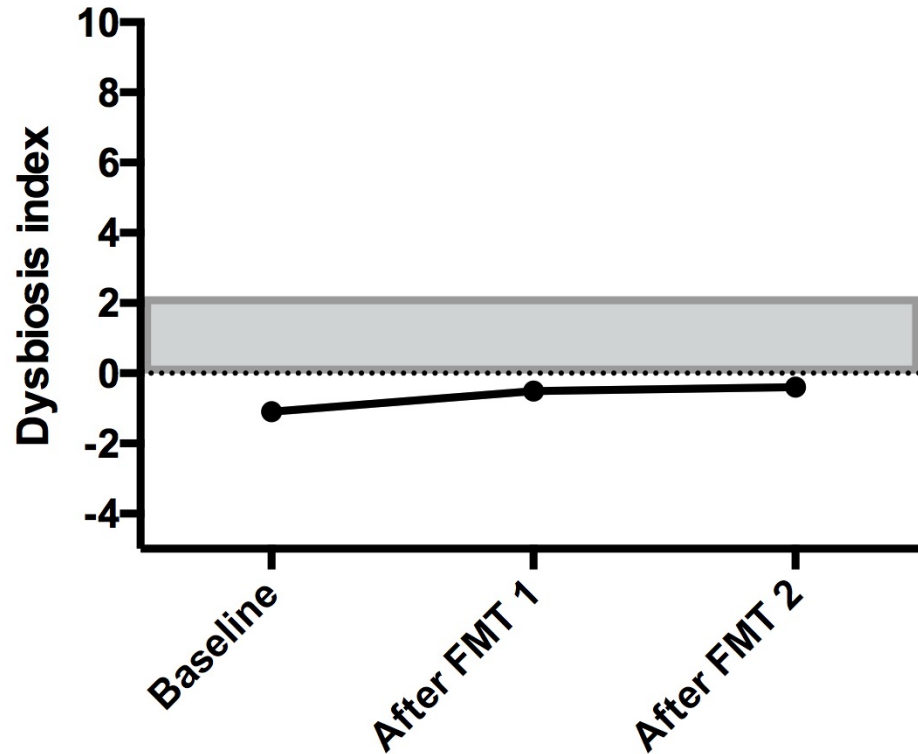
Main complaint: lethargy, anorexia, abdominal pain, occasional vomiting +/- diarrhea, weight loss


Partially steroid-responsive; side effects

Can't taper methylpred. below 0.4 mg/kg q48h, even with addition of 2nd line immunomodulatory (MMF)

FMT – excellent clinical response, started playing, more active, weight gain

Taper methylpred. to 0.2 mg/kg EOD

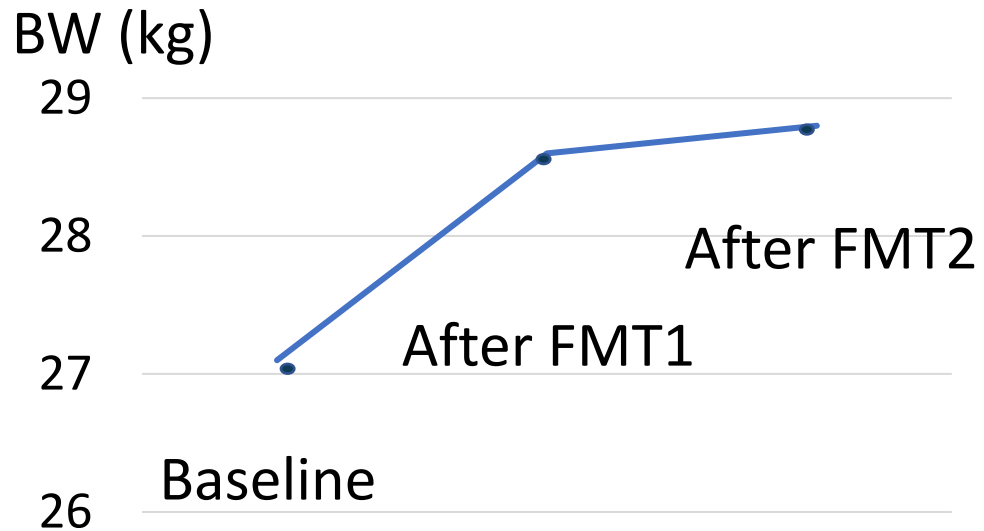




“Alma”, spayed female Golden R., 5 Y/A, P-IRE

Remarkable weight gain after FMT 1

Same amount of food and medication



Fecal metabolomics: prior to FMT marked alterations of fecal lipid profiles (sterols and fatty acids)

Extreme levels of coprostanol (x 24 of RI), very high levels of oleate (butyl) and delta sterol → severe fat malabsorption

Lipid profiles normalized after FMT 1 + body weight!

“Alma”, spayed female Golden R., 5 Y/A, P-IRE



Review

Microbial Reduction of Cholesterol to Coprostanol: An Old Concept and New Insights

Aicha Kriaa , Mélanie Bourgin, Héra Mkaouar, Amin Jablaoui, Nizar Akermi, Souha Soussou, Emmanuelle Maguin and Moez Rhimi *

UMR 1319 Micalis, INRA, Microbiota Interaction with Human and Animal Team (MIHA), AgroParisTech,

FMT – more indications than diarrhea



Article

Clinical Effects of Faecal Microbiota Transplantation as Adjunctive Therapy in Dogs with Chronic Enteropathies—A Retrospective Case Series of 41 Dogs

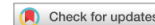Linda Toresson ^{1,2,*}, Thomas Spillmann ¹, Rachel Pilla ³, Ulrika Ludvigsson ², Josefin Hellgren ², Gunilla Olmedal ² and Jan S. Suchodolski ³

31 responders > 8 previously underweight dogs gained weight

JAVMA

Repeated fecal microbiota transplantation in dogs with chronic enteropathy can decrease disease activity and corticosteroid usage

Linda Toresson, DVM, PhD^{1,2*}; Ulrika Ludvigsson, DVM²; Gunilla Olmedal, DVM²; Josefin Hellgren, DVM²; Michaela Toni, DVM²; Paula R. Giaretta, MedVet, DACVP, PhD¹; Jan S. Suchodolski, Dr med vet, PhD, DACVM¹



OPEN

Effect of faecal microbial transplantation on clinical outcome, faecal microbiota and metabolome in dogs with chronic enteropathy refractory to diet

C. G. Vecchiato¹, M. C. Sabetti², C. H. Sung³, F. Sportelli¹, C. Delsante¹, C. Pinna¹, M. Alonzo⁴, D. Erba⁴, J. S. Suchodolski³, R. Pilla³, M. Pietra¹, G. Biagi¹ & F. Procoli⁴

Significant weight gain 30 d. post FMT (T0 = 24 (3.5–50) vs. T1 = 26 (3.4–52))



28 responders > 9 previously underweight dogs gained weight

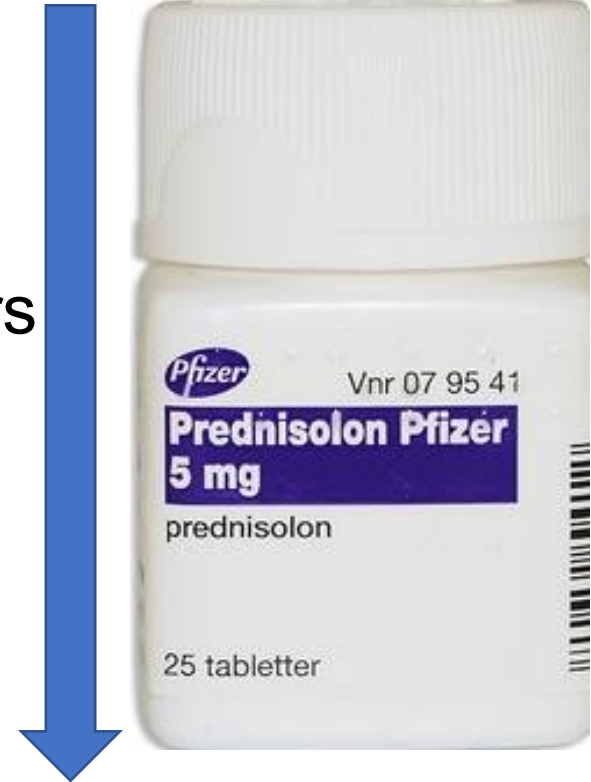Can FMT reduce corticosteroid usage?



Article
**Clinical Effects of Faecal Microbiota Transplantation
as Adjunctive Therapy in Dogs with Chronic Enteropathies—
A Retrospective Case Series of 41 Dogs**

Linda Toresson ^{1,2,*}, Thomas Spillmann ¹, Rachel Pilla ³, Ulrika Ludvigsson ², Josefin Hellgren ²,
Gunilla Olmedal ² and Jan S. Suchodolski ³

1. ↓ maintenance corticosteroid dosage **32%** of responders
2. ↓ /stop maintenance corticosteroid dosage **46%** of resp.
(median ↓↓ 34% (range 25-63))



JAVMA



Repeated fecal microbiota transplantation in dogs with chronic enteropathy can decrease disease activity and corticosteroid usage

Linda Toresson, DVM, PhD^{1,2*}; Ulrika Ludvigsson, DVM²; Gunilla Olmedal, DVM²; Josefin Hellgren, DVM²;
Michaela Toni, DVM²; Paula R. Giarretta, MedVet, DACVP, PhD¹; Jan S. Suchodolski, Dr med vet, PhD, DACVM¹

FMT protocol; Evidensia Specialist Animal Hospital, Helsingborg

1. (Fresh) or **frozen** feces, 5 gr/kg BW of the recipient; dogs 25 kg > 3 gr/kg BW
2. Remove visible grass etc, blend feces w NaCl in blender to suitable texture (1:1 - 1:2 often needed). "Thick smoothie"
3. Face shield recommended
4. Filtrate w colander
5. Aspirate in 60 ml feeding syringes
6. Recipient – walked for 30 minutes prior to transplantation. Rectal palpation (empty??)



FMT protocol; Evidensia Specialist Animal Hospital, Helsingborg

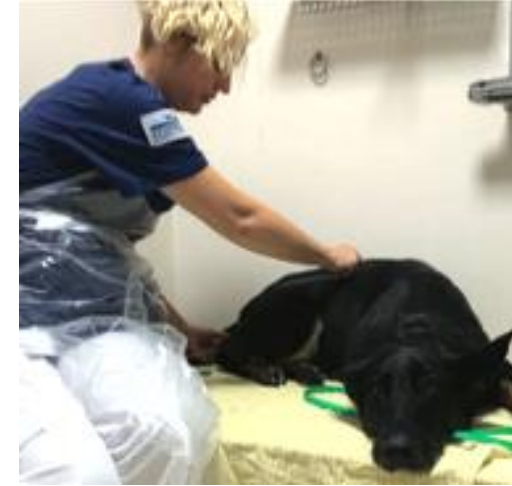(No food 6-8 hrs prior to procedure to avoid gastrocolic reflex?)

Sedation optional – (Acepromazine 0.1 mg/kg in dogs)

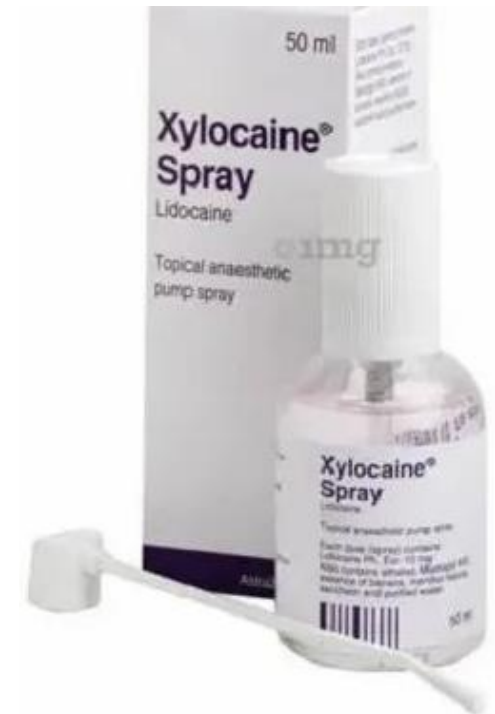Measure the catheter – from the tip to the level of the last rib – marker!

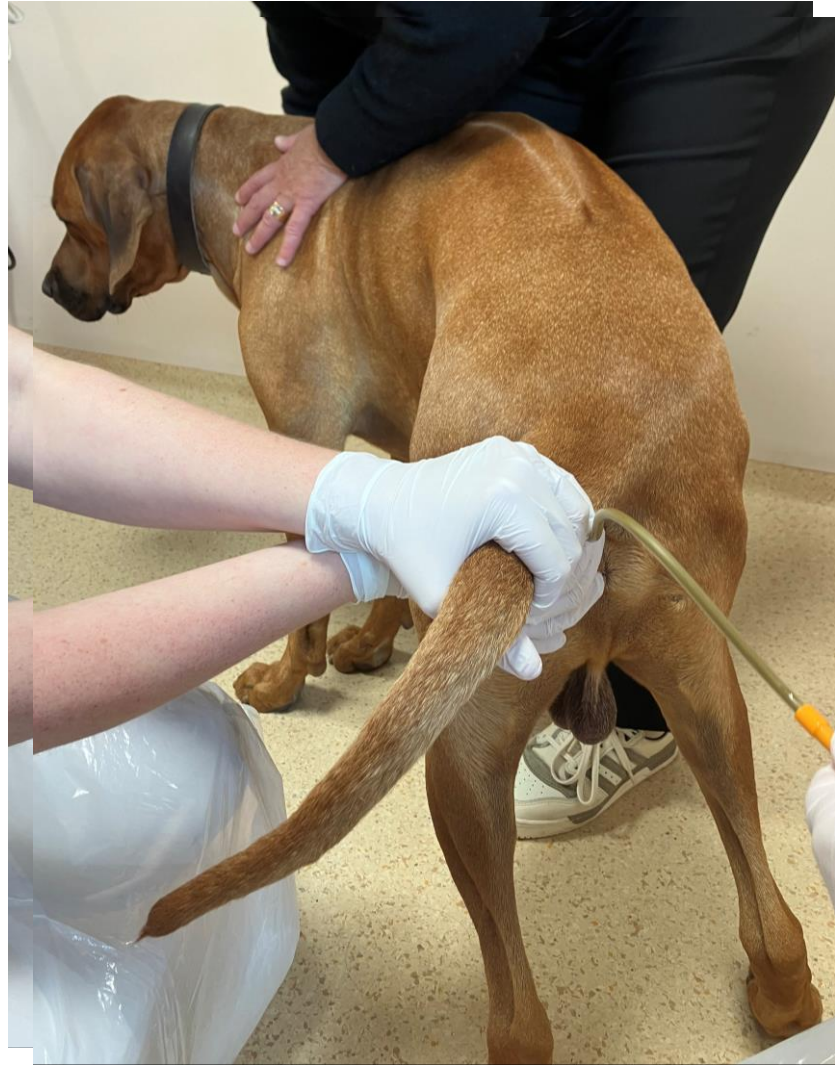
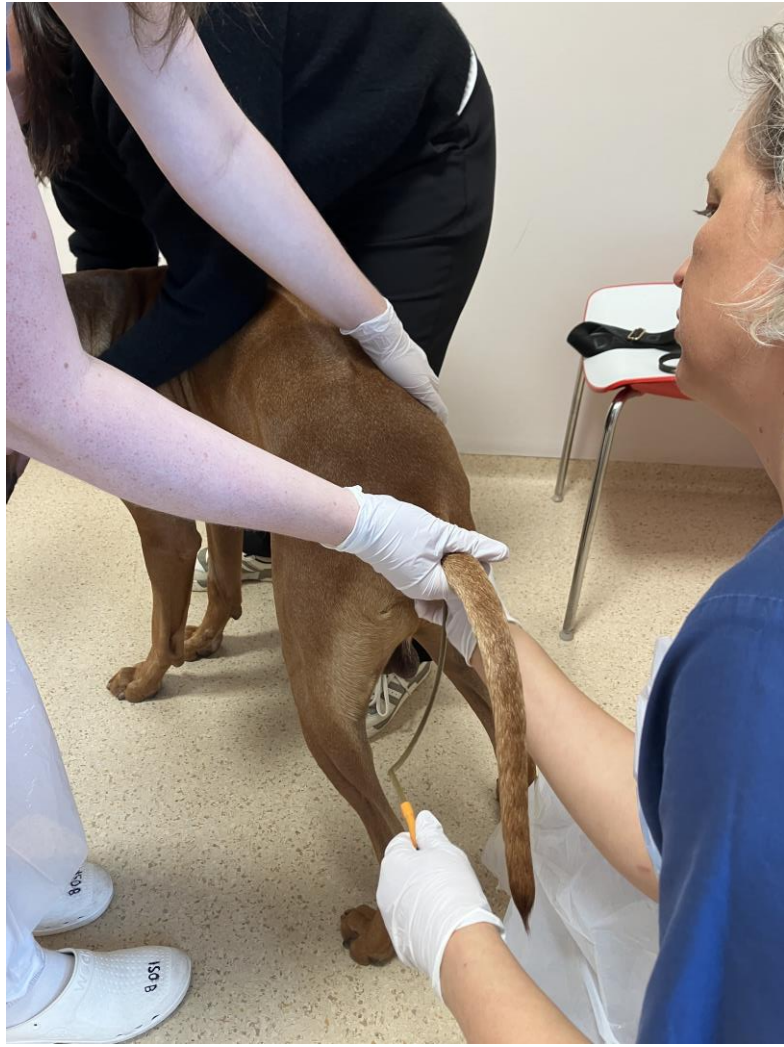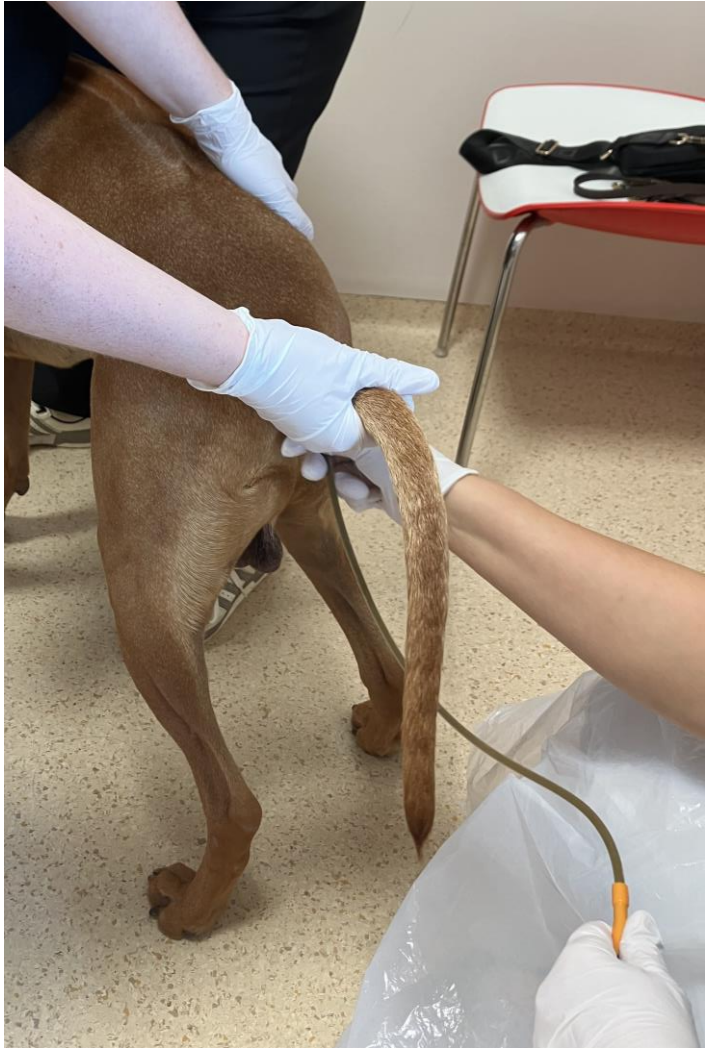Attach the catheter to the syringe, fill the catheter with the transplant

Insert the catheter after generous lubrication



+





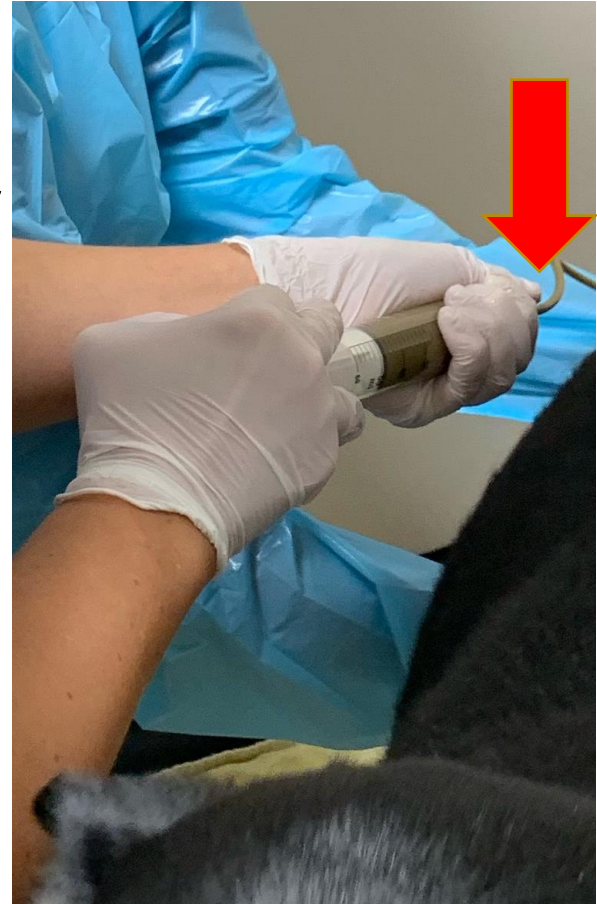FMT protocol; Evidensia Specialist Animal Hospital, Helsingborg

Position – standing dog or lying on the abdomen

Hold a tight grip on the connection between the catheter and the syringe, give the transplant. Remove the catheter

Let the dog owner drive home slowly, no walks or food for a few hours

Carry the dog to the car – move as little as possible!



- Several catheter types can be used
- 16 F straight but flexible suction catheters for most dogs
- 14 F catheters for cats and miniature dogs
- Atraumatic, rounded catheter tips



Frozen feces

Thaw in a fridge over night, or in a 37 °C water bath


10% glycerol can be added to fecal slurry before freezing (1:10) – can be stored in freezer for 3 months

Improved viability in some bacterial species upon thawing

No published studies comparing efficacy off fecal slurry with/without glycerol

Multiple studies and case reports on FMT showing good effect without adding glycerol

Frozen feces without glycerol – use within one month



“Hera”, spayed female Norw. Forest cat, 5.5 Y/A, NRE

Diarrhea for 12 months, defecates x 2, often excess mucus. Vomits intermittently. Very good appetite, alert, gains weight very easily


Standard work-up NAD

Endoscopically retrieved biopsies: Moderate LPE + colitis

Some response to high doses of corticosteroids, fructosamine ↑↑

Non-responsive to cyclosporine, probiotics, olsalazine, chlorambucil and multiple dietary trials

Ultrasound scan: Mildly increased wall thickness colon, mild-moderate enlargement colonic lymph nodes



“Hera”, spayed female Norw. Forest cat, 5.5 Y/A, NRE

After FMT 1: no improvement

After FMT 2: marked improvement, fecal score improved from 5-7/7 to 4/7

FMT 3: Defecated actively when sedation was reversed – not the same positive effect as after FMT2

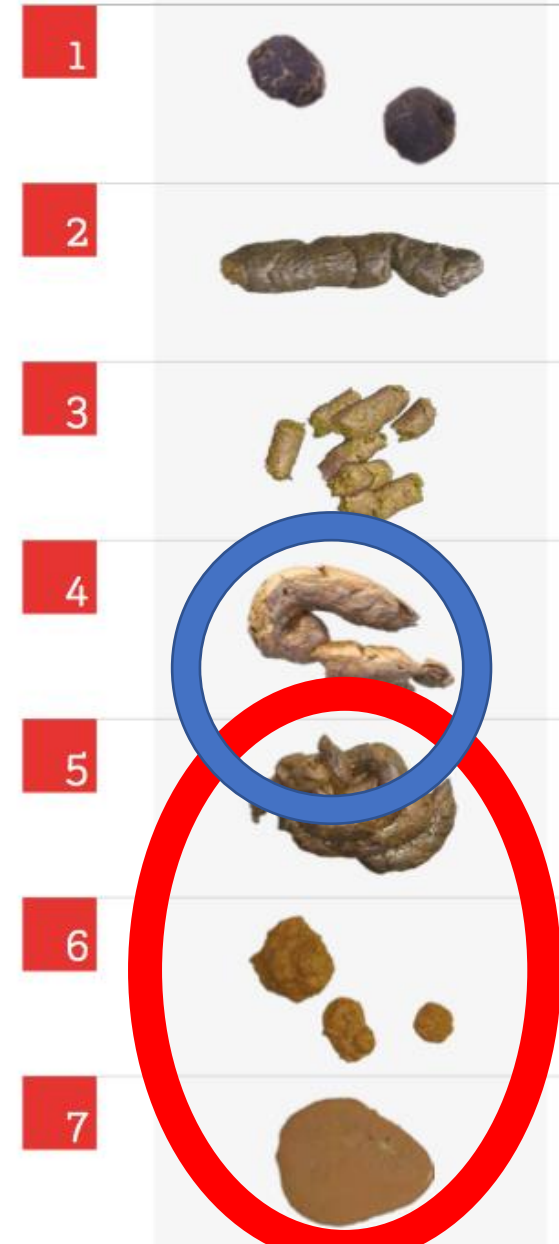Lyophilized capsule 1 EOD started 4 w. post FMT 3

1.5 months post FMT capsules: Feces 4-(5)/7 x 2

No flare-up of watery diarrhea, vomits 1/month

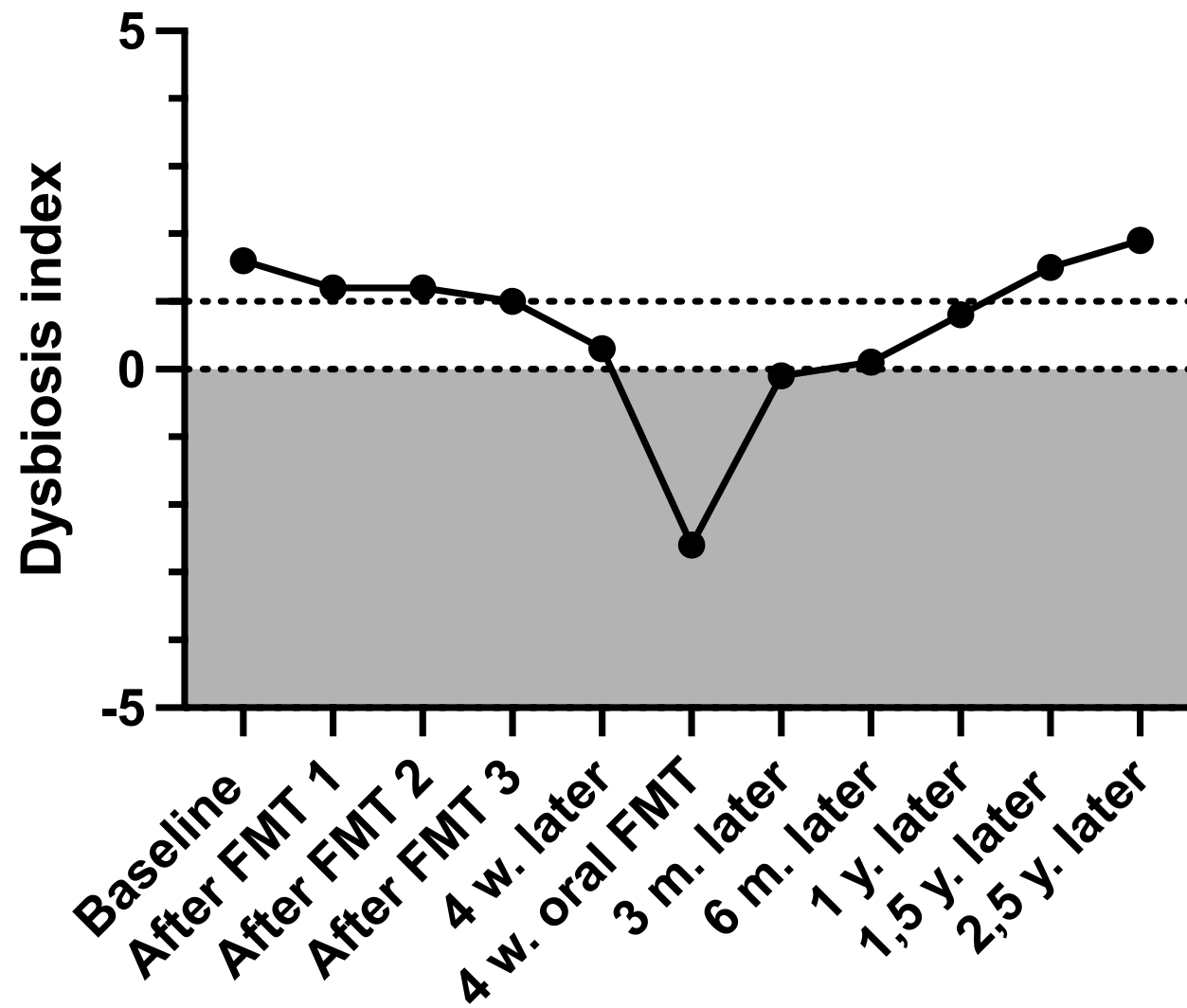
Fecal Scoring Chart

SCORE SPECIMEN EXAMPLE






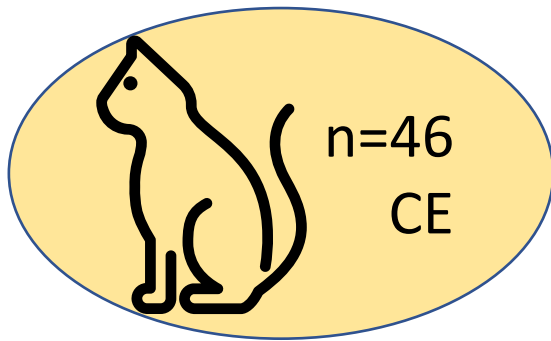
DI Hera



Article


Microbiome Responses to Fecal Microbiota Transplantation in Cats with Chronic Digestive Issues

Connie A. Rojas ^{1,2}, Zhandra Entrolezo ³, Jessica K. Jarett ³, Guillaume Jospin ³ , Dawn D. Longsbury ³, Alex Martin ³, Jonathan A. Eisen ^{1,2}  and Holly H. Ganz ^{3,*}



X 50 d.


Disease activity




STANDARD ARTICLE **OPEN ACCESS**

Small Animal Internal Medicine Gastroenterology

Single Enema Fecal Microbiota Transplantation in Cats With Chronic Enteropathy



- 19 cats w. CIE, 9 w small cell GI lymphoma
- 11 FMT group (1 single FMT), 17 control cats
- No difference in disease activity or dysbiosis index between groups at baseline or aafter 30 days
- Too few FMTs?



FMT donor screening –recommendations

Age/signalment/environment

- minimum 12 months to middle aged
- clinically healthy (no abnormalities found on clinical examination or history)
- CIBDAI < 3
- acceptable body condition score (BCS 4-6/9)
- CBC + serum biochemistry WNL
 - No raw food diets
 - No antibiotics (min. 6 mths)
- Indoor cats from single households ➡ minimize risk of infections
- Cats - minimum 6 weeks in the household

Advances in Small Animal Care 5 (2024) 79–107

ADVANCES IN SMALL ANIMAL CARE

Clinical Guidelines for Fecal Microbiota Transplantation in Companion Animals

Jenessa A. Winston, DVM, PhD, DACVIM (Small Animal Internal Medicine)^{a,*},
Jan S. Suchodolski, DrMedVet, PhD, DACVM, AGAF^b,
Frederic Gaschen, DrMedVet, Drhabl, DACVIM (Small Animal Internal Medicine), DipECVIM-CA^c,
Kathrin Busch, DVM, Dr Med Vet, DECVIM^d,
Sina Marsilio, Dr med vet, PhD, DACVIM (Small Animal Internal Medicine), DipECVIM-CA^e,
Marcio C. Costa, DVM, DVSc, PhD^f, Jennifer Chaitman, VMD, DACVIM (Small Animal Internal Medicine)^g,
Emily L. Coffey, DVM, DACVIM (Small Animal Internal Medicine), PhD^h,
Julien R.S. Dandrieux, BSc, Dr Med Vet, PhD, DACVIM (Small Animal Internal Medicine)ⁱ,
Arnon Gal, DVM, MSc, PhD, DACVIM, DACVP^j,
Tracy Hill, DVM, PhD, DACVIM (Small Animal Internal Medicine)^k, Rachel Pilla, DVM, PhD^{b,l},
Fabio Procoli, DVM, MVetMed, DACVIM, DipECVIM-CA, MRCVS^m,
Silke Salavati Schmitz, Dr Med Vet, PhD, DipECVIM-CA, FHEA, FRCVSⁿ,
M. Katherine Tolbert, DVM, PhD, DACVIM (Small Animal Internal Medicine, Small Animal Nutrition)^o,
Linda Toresson, DVM, PhD^o, Stefan Unterer, DVM, Dr med vet, Dr habilit, DECVIM-CA^o,

FMT donor screening – current recommendations

Screening (recommended)

- Normal Dysbiosis Index
- *Salmonella*
- *Campylobacter jejuni*
- *Giardia* and *Cryptosporidium*
- other intestinal parasites with centrifugal fecal flotation
- Cats +
 - *Tritrichomonas foetus*
 - Enteric coronavirus (PCR recommended; once for cats in indoor single-cat-household)
 - FIV and FeLV

Frequency

- Minimum every 6 months, potentially more frequent based on risk /environment

Advances in Small Animal Care 5 (2024) 79–107

ADVANCES IN SMALL ANIMAL CARE


Clinical Guidelines for Fecal Microbiota Transplantation in Companion Animals



Jenessa A. Winston, DVM, PhD, DACVIM (Small Animal Internal Medicine)^{a,*},
Jan S. Suchodolski, DrMedVet, PhD, DACVM, AGAF^b,
Frederic Gaschen, DrMedVet, Drhabil, DACVIM (Small Animal Internal Medicine), DipECVIM-CA^c,
Kathrin Busch, DVM, Dr Med Vet, DECVIM^d,
Sina Marsilio, Dr med vet, PhD, DACVIM (Small Animal Internal Medicine), DipECVIM-CA^e,
Marcio C. Costa, DVM, DVSc, PhD^f, Jennifer Chaitman, VMD, DACVIM (Small Animal Internal Medicine)^g,
Emily L. Coffey, DVM, DACVIM (Small Animal Internal Medicine), PhD^h,
Julien R.S. Dandrieux, BSc, Dr Med Vet, PhD, DACVIM (Small Animal Internal Medicine)ⁱ,
Arnon Gal, DVM, MSc, PhD, DACVIM, DACVP^j,
Tracy Hill, DVM, PhD, DACVIM (Small Animal Internal Medicine)^k, Rachel Pilla, DVM, PhD^{b,l},
Fabio Procoli, DVM, MVetMed, DACVIM, DipECVIM-CA, MRCVS^m,
Silke Salavati Schmitz, Dr Med Vet, PhD, DipECVIM-CA, FHEA, FRCVSⁱ,
M. Katherine Tolbert, DVM, PhD, DACVIM (Small Animal Internal Medicine, Small Animal Nutrition)^b,
Linda Toresson, DVM, PhDⁿ, Stefan Unterer, DVM, Dr med vet, Dr habil, DECVIM-CA^o,

Indications for FMT in CE

- Young animals with chronic diarrhea
 - after infections or antibiotic use
 - not responding to treatment



Start your own
fecal bank
ASAP!!!!!!

start

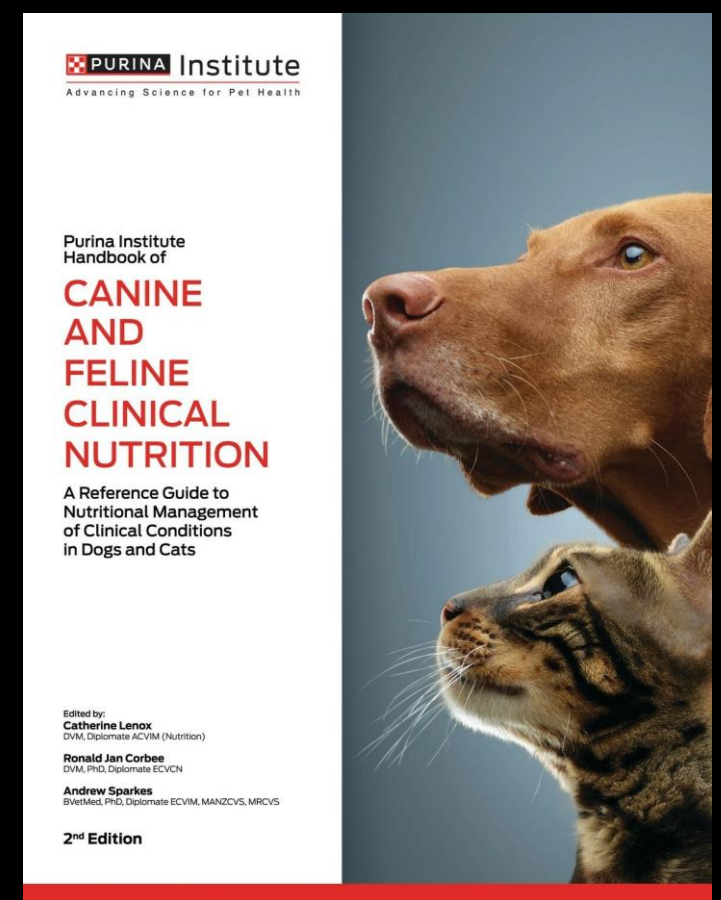long antibiotics
long GI inflammation

- Similar indications in cats



PURINA
PRO PLAN
symposium

Thank you!



**Clinical tools: Utilizing FMT
in practice**

